

CASE REPORT

Open Access



# Prenatal identification of an inverted duplicated 13q marker chromosome with a neocentromere

Liselot van der Laan<sup>1</sup>, Daniel R. Hoekman<sup>1</sup>, Esther J. Wortelboer<sup>1</sup>, Marcel M. A. M. Mannens<sup>1</sup> and Angelique J. A. Kooper<sup>1\*</sup>

## Abstract

In this case report, we describe a rare prenatal finding of a small marker chromosome. This marker chromosome corresponds to an inverted duplication of the 13q region 13q31.1q34 (or 13q31.1 → qter) with a neocentromere, detected during genetic analysis of a chorionic villus sample in a fetus with multiple congenital anomalies after a normal prenatal screening result by noninvasive prenatal testing.

**Keywords** Neocentromere, Marker chromosome, False-negative NIPT, Placental mosaicism

## Background

The centromere is a chromosomal structure that allows cells to divide their genetic material during meiotic and mitotic cell divisions. Centromeres are usually characterized by tandemly repeated alpha satellite DNA and heterochromatin [1]. A neocentromere is a new centromere at a location, normally not centromeric, and are centromeric regions without alpha satellite DNA. They are able to form a primary constriction and assemble a functional kinetochore and carry out the function of a normal centromere. This shows that centromere formation is not only dependent on primary DNA sequence [2]. The majority of neocentromeres in marker chromosomes are an inverted duplication of the distal parts of a chromosome arm resulting in partial tri- or tetrasomy [3]. A small supernumerary marker chromosome (sSMC) is an additional chromosome that usually lacks a

distinct banding pattern and which can be rarely identified by conventional banding [4]. Therefore additional techniques are necessary to characterize the origin of the marker chromosome. We present a case of a sSMC originating from an inverted duplication of distal 13q31.1q34 found in a chorionic villus sample (CVS) in a fetus with multiple congenital anomalies. Previously, the 31 year-old pregnant woman received a normal screening result of noninvasive prenatal testing (NIPT). Both cytogenetic and molecular techniques were used to characterize this finding.

## Case presentation

We present a case of a primigravida (conceived by intracytoplasmic sperm injection) who underwent targeted NIPT in the Dutch TRIDENT-2 study [5] with a normal result for chromosomes 13, 18 and 21. At 14+3 weeks of gestation, a routine structural ultrasound scan revealed multiple anomalies: a cerebral midline defect (compatible with holoprosencephaly), polydactyly, and a congenital cardiac defect (Fig. 1). Chorionic villus sampling was performed. Based on the ultrasound anomalies, the pregnancy was terminated at 17 weeks of gestation. Postpartum physical examination of the fetus showed leg

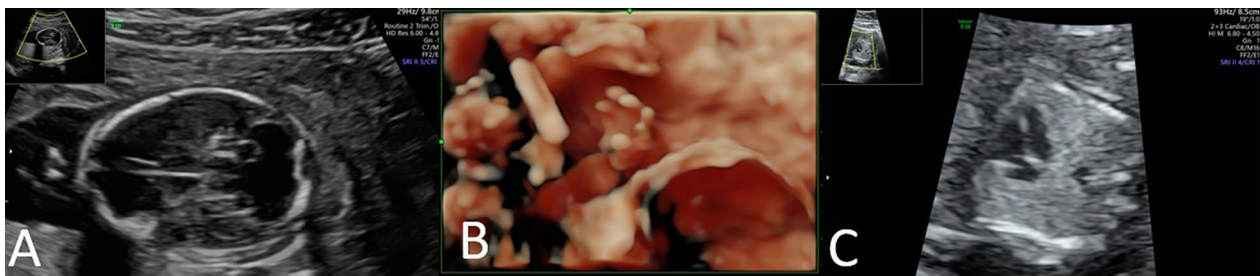
\*Correspondence:

Angelique J. A. Kooper  
a.j.kooper@amsterdamumc.nl

<sup>1</sup> Department of Human Genetics, Amsterdam Reproduction and Development Research Institute, Amsterdam University Medical Centers, University of Amsterdam, Amsterdam, The Netherlands



© The Author(s) 2023. **Open Access** This article is licensed under a Creative Commons Attribution 4.0 International License, which permits use, sharing, adaptation, distribution and reproduction in any medium or format, as long as you give appropriate credit to the original author(s) and the source, provide a link to the Creative Commons licence, and indicate if changes were made. The images or other third party material in this article are included in the article's Creative Commons licence, unless indicated otherwise in a credit line to the material. If material is not included in the article's Creative Commons licence and your intended use is not permitted by statutory regulation or exceeds the permitted use, you will need to obtain permission directly from the copyright holder. To view a copy of this licence, visit <http://creativecommons.org/licenses/by/4.0/>. The Creative Commons Public Domain Dedication waiver (<http://creativecommons.org/publicdomain/zero/1.0/>) applies to the data made available in this article, unless otherwise stated in a credit line to the data.



**Fig. 1** Ultrasound anomaly scan **A** Midline defect cerebral (compatible with holoprosencephaly) **B** Polydactyly and **C** Congenital cardiac defect (suspect for ventricular septal defect)

contractures and polydactyly of the feet. Fetal autopsy was not performed.

### Material and methods

Previously, NIPT was performed as part of the Dutch TRIDENT-2 study (Trident = Trial by Dutch laboratories for Evaluation of NIPT). The method that was used shortly involved genome-wide shallow massively parallel shotgun sequencing and genome-wide analysis with WISECONDOR that has a resolution of approximately 15 Mb at a sequencing depth of about 10 to 12 million reads per sample.

Sex chromosomes were not analyzed. Parents choose to have a targeted NIPT analysis for the chromosomes 13, 18 and 21.

After receiving the CVS, Trypsin Express was used to remove the cytotrophoblasts layer. Cytotrophoblast cells were stored. Subsequently, routine Quantitative Fluorescence Polymerase Chain Reaction (QF-PCR) and array-CGH analyses were conducted on DNA isolated from the mesenchymal core cells of the villi. In parallel, cell culture on the mesenchymal core cells was performed in duplicate using two different cell culture media (Amnioxmax C100 and Chang D medium), according to standard procedures of the Amsterdam UMC, Human Genetics department. QF-PCR analysis on DNA from the mesenchymal core cells was performed using the QST<sup>®</sup>Rplusv2 kit from Elucigene (Manchester, UK) following the instructions of the manufacturer. Interpretation of the data was performed according standard and accredited procedures of the Amsterdam UMC, Human genetics department.

Array-CGH microarray analysis was performed on DNA from the mesenchymal core cells using 180 k microarray slides from Agilent Technologies (Santa Clara, CA), following manufacturer's protocols using a mixed pool of 50 healthy males as a reference. Scanned images were analyzed by using Agilent Genomic Workbench version 6.5 and Cartagenia (Agilent Technologies).

Interpretation of CNV data was performed as described in the guidelines of the lab.

Fluorescence In Situ Hybridization (FISH) was performed according to standard procedures of the Amsterdam UMC, Human Genetics department. The following probes were used; centromere 12 (CEP12), LSI D13S319 (13q14.3) and LSI 13q34 from Vysis Abbott (Inc, London, United Kingdom).

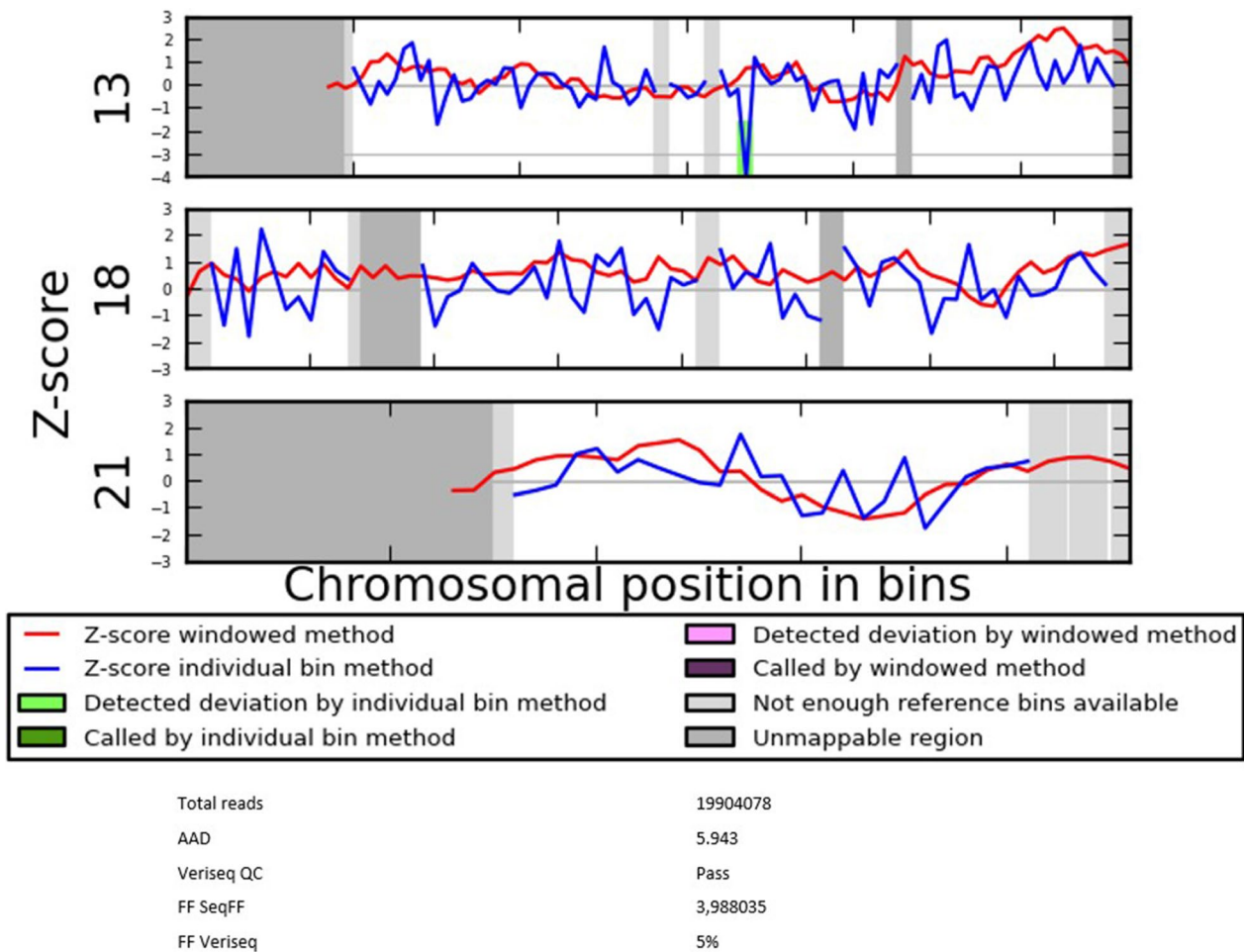
### Results

Parents received a normal result of the NIPT screening. The corresponding NIPT profile is shown in Fig. 2.

The QF-PCR profile on DNA from the mesenchymal core cells was normal for chromosomes 18, 21, X and Y consistent with a male profile. However, due to insufficient informative markers for chromosome 13, an additional kit for chromosome 13 (QST<sup>®</sup>R- 13) was used. Unexpectedly, two QF-PCR markers D13S762 and D13S797, located in the 13q terminal region, showed an abnormal profile with a 3:1 ratio (Fig. 3A). In conclusion, there are two abnormal markers in the terminal region, two normal markers for chromosome 13 (D13S800 and D13S325), whereas the other four markers for chromosome 13 were not informative.

Subsequently, array-CGH was performed, revealing a homozygous copy number gain of approximately 31.7 Mb in the distal part of the long arm of chromosome 13 (13q31.1q34). This region contains multiple OMIM morbid genes (*SLITRK1*, *SLITRK6*, *GPC6*, *DCT*, *TGDS*, *CLDN10*, *DZFI1*, *DNAJC3*, *ZIC2*, *PCCA*, *NALCN*, *FGF14*, *TPP2*, *ERCC5*, *SLC10A2*, *DAOA*, *LIG4*, *IRS2*, *COL4A1*, *COL4A2*, *NAXD*, *CARS2*, *ING1*, *ATP11A*, *F7*, *F10*, *PROZ*, *GRK1*, *CHAMP1*) (Fig. 4). This finding corresponded with the earlier result of the QF-PCR test.

Additional karyotyping of cultured mesenchymal core cells revealed a small sSMC in all metaphases with a centromere located in a non-centromere region (neocentromere). The normal chromosomes 13 and the marker chromosome stained by quinacrine banding (Q-band) are shown in Fig. 5C.



**Fig. 2** WISECONDOR plot showing the normal NIPT result for the chromosomes 13, 18 and 21

To confirm that the marker chromosome consisted of the duplicated region of chromosome 13 detected by array analysis, metaphase FISH analysis was performed using a whole-chromosome painting probe for chromosome 13 (WCP13) and a probe for the region 13q34 (13qter). A centromere probe for chromosome 12 (CEP12) was used as a control probe for euploidy. The WCP13 probe painted both normal chromosomes 13 and the marker chromosome, indicating the marker chromosome originates from chromosome 13. Subsequently, the probe for the region 13q34 (13qter) showed a signal at both distal regions of the marker chromosome, confirming the partial tetrasomy of 13q originated from an inverted duplicated neocentric marker chromosome derived from the distal region of 13q (Fig. 5). In total 50 metaphases were examined.

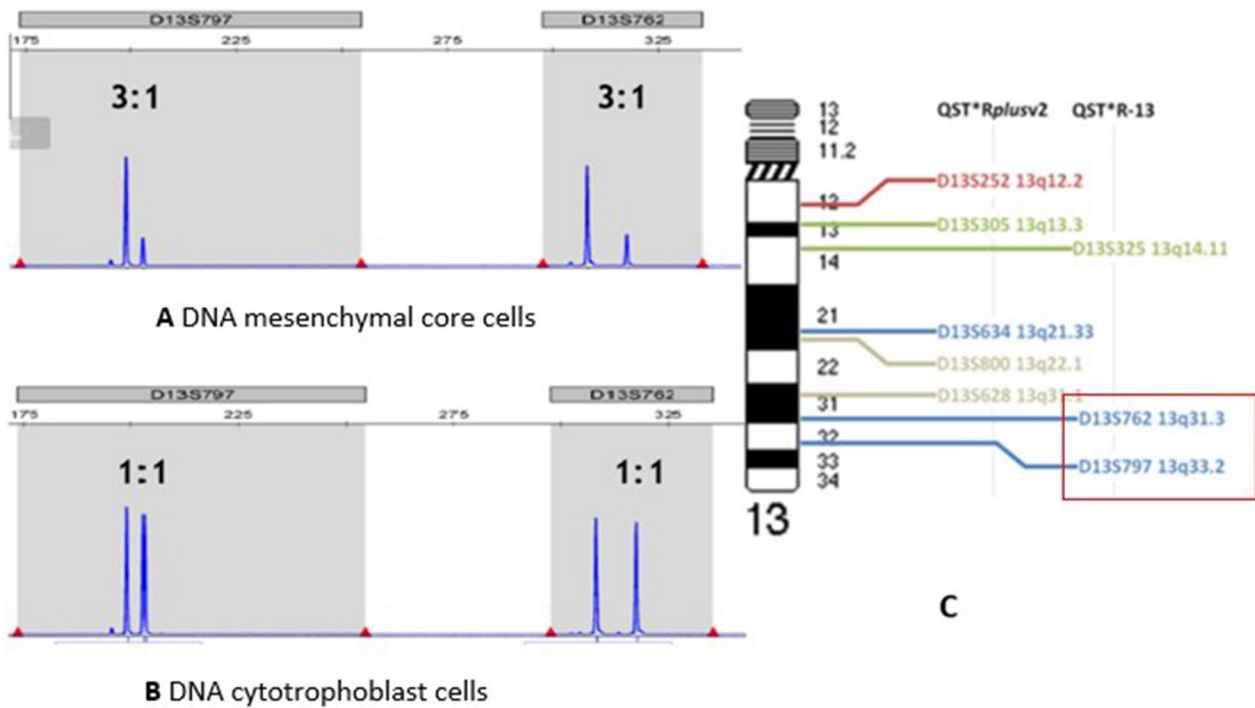
To address the discrepancy between the normal NIPT screening result and the abnormal array finding of the mesenchymal core cells in the CVS, DNA isolated from the cytotrophoblasts cell suspension was examined by

QF-PCR with markers for chromosome 13. All informative markers for chromosome 13 showed a normal pattern (ratio 1:1) (Fig. 1b).

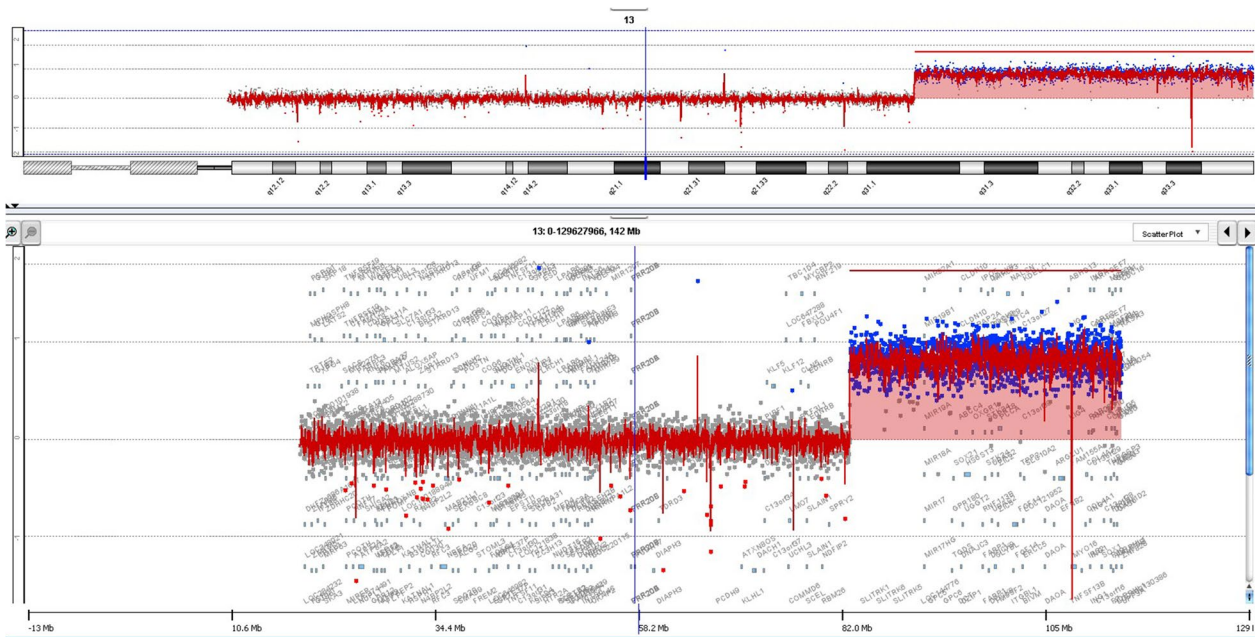
### Discussion

We report a CVS that showed a partial tetrasomy of distal 13q resulted from an inverted duplicated neocentric marker chromosome 13. This aberration was found with QF-PCR and array-CGH and later confirmed with karyotyping and FISH in the mesenchymal core cells of the CVS.

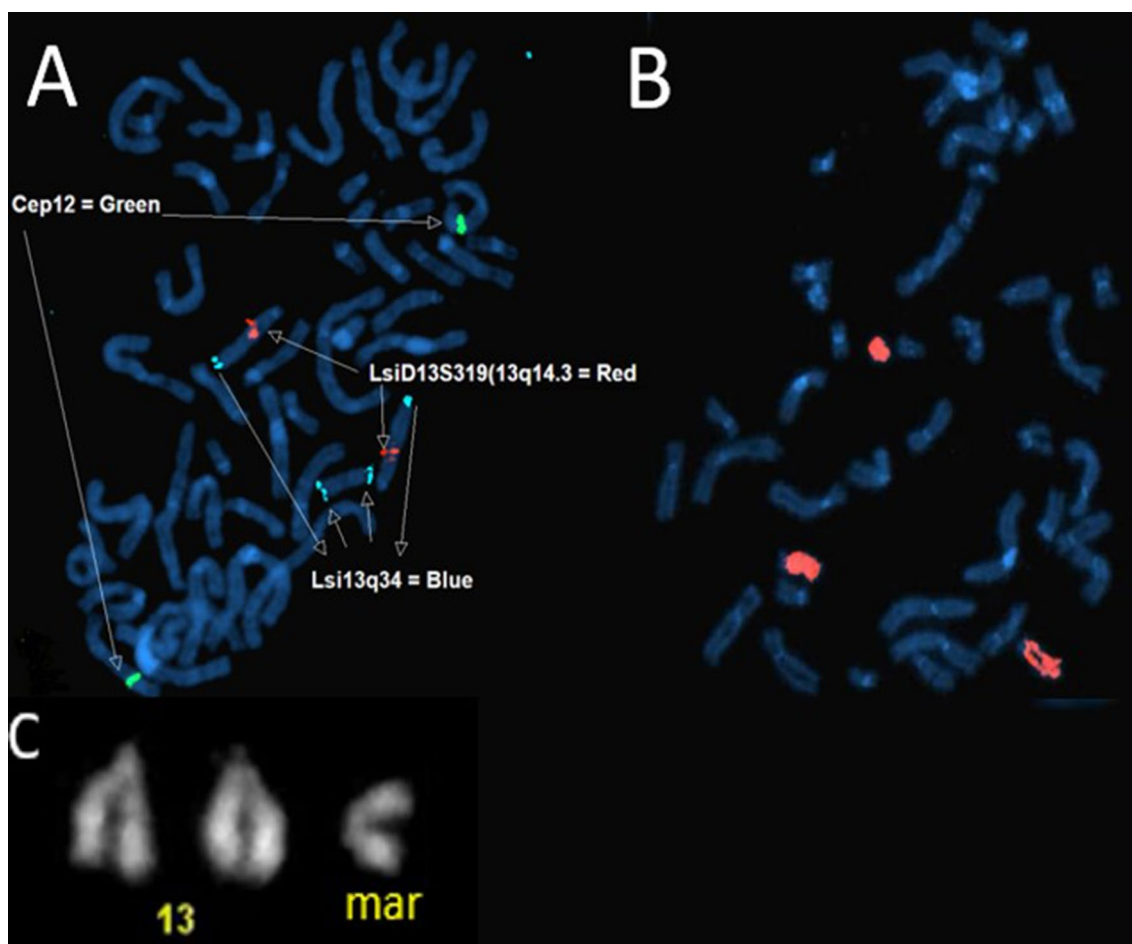
Previously, the couple underwent NIPT screening with a normal test result. During routine cytogenetic testing of CVS, in our laboratory the cytotrophoblasts layer is removed and stored as a backup, while diagnostic testing is conducted on the mesenchymal core cells. The partial tetrasomy of distal 13q appeared to be present in the mesenchymal core cells but not in the cytotrophoblasts. These two opposing cytogenetic constitutions of the fetoplacental compartments result in a false-negative NIPT



**Fig. 3** **A** 3:1 ratio for the STR markers D13S797 and D13S762 in DNA from mesenchymal core cells. **B** 1:1 ratio for D13S797 and D13S762 in DNA from cytotrophoblasts cells. **C** STR marker location, idiogram STR markers for chromosome 13. Only the framed markers are abnormal



**Fig. 4** Array-CGH profile of chromosome 13 showing the homozygous copy number gain of approximately 31.7 Mb in the distal part of the long arm of chromosome 13: arr[GRCh37] 13q31.1q34(83416907\_115105806)×4 (hg19). The upper part of the figure displays chromosome 13, and below it, there is a zoomed-in view of chromosome 13



**Fig. 5** The FISH results **A** Metaphase FISH analysis was performed using the LSI D13S319 (13q14.3, red) and LSI 13q34 (blue) probes from Vysis Abbott and a centromere probe for chromosome 12 (CEP12) was used as a control probe. **B** The whole chromosome painting probe for chromosome 13 (WCP13) painted both normal chromosomes 13 and the marker chromosome, indicating the marker chromosome originates from chromosome 13. **C** The normal chromosomes 13 and the marker chromosome stained by quinacrine banding (Q-band)

screening result [6, 7]. Due to the severity of the ultrasound anomalies, the parents terminated the pregnancy without consent for autopsy or additional postpartum testing.

Partial tetrasomy 13q has been described prenatally in the literature only twice. Mascarenhas et al. and Hadad et al. both described a fetus with a sSMC consisting of an inverted duplication of the distal portion of chromosome 13q [8, 9]. The molecular and clinical findings in those two cases are compared with our case in Table 1.

We do not see an overlap with the cases from Mascarenhas et al. and Hadad et al. There was no autopsy performed in our case and therefore it might be possible that some anomalies remained undetected. Liehr et al. describes postnatal patients with sSMC of chromosome 13 but they are all present in mosaic and do not overlap in phenotype with our case [4]. In general partial tetrasomy of 13q has a reported association with a variable

phenotype including microphthalmia, ear abnormalities, hypotelorism, facial dysmorfisms, urogenital defects, pigmentation and skin defects, and severe learning difficulties [10–13].

The formation of a neocentromeric marker of distal 13q, band 13q31 appears to be a known hotspot for neocentromere formation [14, 15]. In our case this additional sSMC was part of a mosaic placenta, present in the mesenchymal core cells, but absent in the trophoblasts. While we found no evidence of mosaicism in the mesenchymal cells of the villi, it is noteworthy that we did not assess the genotype of the fetus, as access to amniotic fluid or a postpartum skin biopsy was unavailable. Consequently, the potential existence of a mosaicism in the fetus cannot be ruled out and might explain the different phenotype.

This case also illustrates that a normal NIPT screening result does not exclude chromosomal aberrations

**Table 1** Molecular and clinical data in a fetus with partial tetrasomy 13q

	Mascarenhas et al. [8]	Haddad et al. [9]	Present case (2023)
Region	q31-qter	q31-qter	q31.1-qter
Neocentromere location	13q31	13q31	13q31.1
Mosaicism (%)	100	100	100
Sex	F	M	M
Gestational age	23 WG	17 WG	17 WG
Growth delay	NA	+	–
Microcephaly	NA	–	–
Macrocephaly	NA	NA	+
Hypertelorism	–	–	–
Hypotelorism	+	–	–
Nose abnormalities	+	+	–
Philtrum	NA	–	–
Cleft palate/lips	–	–	–
High palate	–	–	NA
Microphthalmia	–	–	–
Coloboma	NA	–	NA
Abnormal ears	+	+	–
Heart defects	NA	–	+
Lung defects	NA	–	–
Gastrointestinal malrotation	NA	+	–
Polydactyly	NA	+	+
Skeletal abnormalities	NA	+	+
Genital abnormalities	NA	+	–
Renal defect	+	+	NA
Cerebral midline defect	NA	NA	+

NA not available, WG weeks of gestation

in a fetus and shows the importance of standard ultrasound examination during pregnancy to improve the detection rate of fetal chromosomal abnormalities.

## Conclusions

We describe a fetus with a partial tetrasomy 13q resulting from an inverted duplicated neocentric marker chromosome. The marker chromosome was present in the mesenchymal core layer and absent in the cytotrophoblasts of the villi, and therefore remained undetected by NIPT.

## Abbreviations

sSMC	Small supernumerary marker chromosome
CVS	Chorionic villus sample
NIPT	Non-invasive prenatal test
NA	Not available
WG	Weeks of gestation
WCP13	Whole-chromosome painting probe for chromosome 13
TRIDENT-2	Trial by Dutch laboratories for evaluation of NIPT
QF-PCR	Quantitative fluorescence polymerase chain reaction

## Acknowledgements

We would like to thank the parents of our patient for their cooperation and our colleagues from the cytogenetics laboratory; Carol de Koning, Jaime Houterman, Yasmin Stoop, Judith van de Brug, Bart Essink and Jos Roozendaal.

## Author contributions

LL and AJAK performed the laboratory experiments and analysis. DRH and EJW performed the clinical assessment. MMAMM and AJAK supervised the project. LL and AJAK wrote the manuscript and prepared the figures and table. All authors reviewed the manuscript.

## Funding

Not applicable.

## Availability of data and materials

Data are available from the authors on request.

## Declarations

### Ethical approval and consent to participate

The study was conducted in accordance with the regulations of the Medical Ethical Committee (METC) of the Amsterdam UMC, location AMC.

### Consent for publication

We obtained written informed consent from the parents of the participants to publish patients' clinical and genetic information.

**Competing interests**

The authors have no conflicts of interest relevant to this article.

Received: 23 October 2023 Accepted: 17 November 2023

Published online: 30 November 2023

**References**

1. Choo KH. Centromere DNA dynamics: latent centromeres and neocentromere formation. *Am J Hum Genet.* 1997;61(6):1225–33.
2. Amor DJ, Choo KH. Neocentromeres: role in human disease, evolution, and centromere study. *Am J Hum Genet.* 2002;71(4):695–714.
3. Liu J, Jethva R, Del Vecchio MT, Hauptman JE, Pascasio JM, de Chadarévian JP. Tetrasomy 13q32.2qter due to an apparent inverted duplicated neocentric marker chromosome in an infant with hemangiomas, failure to thrive, laryngomalacia, and tethered cord. *Birth Defects Res A Clin Mol Teratol.* 2013;97(12):812–5.
4. Liehr T, Utine GE, Trautmann U, Rauch A, Kuechler A, Pietrzak J, et al. Neocentric small supernumerary marker chromosomes (sSMC)—three more cases and review of the literature. *Cytogenet Genome Res.* 2007;118(1):31–7.
5. van Prooyen SL, Sijm EA, Van Opstal D, Henneman L, Bekker MN, Bax CJ, et al. Clinical impact of additional findings detected by genome-wide non-invasive prenatal testing: Follow-up results of the TRIDENT-2 study. *Am J Hum Genet.* 2022;109(6):1140–52.
6. Grati FR. Chromosomal mosaicism in human fetoplacental development: implications for prenatal diagnosis. *J Clin Med.* 2014;3(3):809–37.
7. Reilly K, Doyle S, Hamilton SJ, Kilby MD, Mone, F. Pitfalls of prenatal diagnosis associated with mosaicism. *Obstet Gynaecol.* 2022.
8. Mascarenhas A, Matoso E, Saraiva J, Tönnies H, Gerlach A, Julião MJ, et al. First prenatally detected small supernumerary neocentromeric derivative chromosome 13 resulting in a non-mosaic partial tetrasomy 13q. *Cytogenet Genome Res.* 2008;121(3–4):293–7.
9. Haddad V, Aboura A, Tosca L, Guediche N, Mas AE, L'Herminé AC, et al. Tetrasomy 13q31.1qter due to an inverted duplicated neocentric marker chromosome in a fetus with multiple malformations. *Am J Med Genet A.* 2012;158a(4):894–900.
10. Dharmadhikari AV, Pereira EM, Andrews CC, Macera M, Harkavy N, Wapner R, et al. Case report: Prenatal identification of a de novo mosaic neocentric marker resulting in 13q31.1→qter tetrasomy in a mildly affected girl. *Front Genet.* 2022;13:906077.
11. Barwell J, Mazzaschi R, Bint S, Ogilvie CM, Elmslie F. A new neocentromere locus on chromosome 13 resulting in mosaic tetrasomy for distal 13q and an asymmetric phenotype. *Am J Med Genet A.* 2004;130a(3):295–8.
12. Dhar SU, Robbins-Furman P, Levy ML, Patel A, Scaglia F. Tetrasomy 13q mosaicism associated with phylloid hypomelanosis and precocious puberty. *Am J Med Genet A.* 2009;149a(5):993–6.
13. Myers JN Jr, Davis L, Sheehan D, Kulharya AS. Mosaic tetrasomy 13q and phylloid hypomelanosis: a case report and review of the literature. *Pediatr Dermatol.* 2015;32(2):263–6.
14. Li S, Malafiej P, Levy B, Mahmood R, Field M, Hughes T, et al. Chromosome 13q neocentromeres: molecular cytogenetic characterization of three additional cases and clinical spectrum. *Am J Med Genet.* 2002;110(3):258–67.
15. Warburton PE. Chromosomal dynamics of human neocentromere formation. *Chromosome Res.* 2004;12(6):617–26.

**Publisher's Note**

Springer Nature remains neutral with regard to jurisdictional claims in published maps and institutional affiliations.

**Ready to submit your research? Choose BMC and benefit from:**

- fast, convenient online submission
- thorough peer review by experienced researchers in your field
- rapid publication on acceptance
- support for research data, including large and complex data types
- gold Open Access which fosters wider collaboration and increased citations
- maximum visibility for your research: over 100M website views per year

**At BMC, research is always in progress.**

Learn more [biomedcentral.com/submissions](https://biomedcentral.com/submissions)

